

7.12 Replacement of a Missing Upper Left Central Incisor: Late Placement of an RC Bone Level Implant, CAD/CAM Zirconia Abutment

E. R. Lorenzana, J. Gillespie

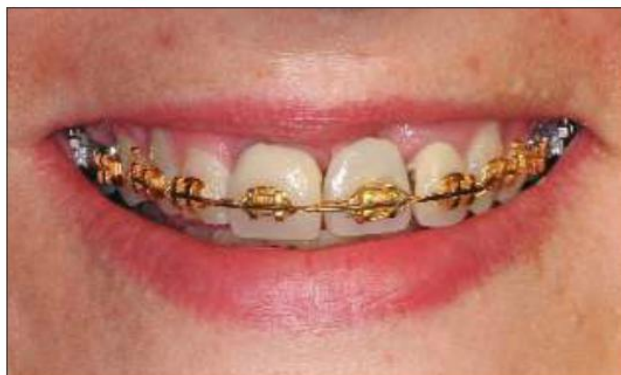

Fig 1 At full smile, the patient presented with a medium to high lip line, exposing the papillae throughout the anterior sextant, but with the upper lip obscuring the gingival margins of the central incisors.

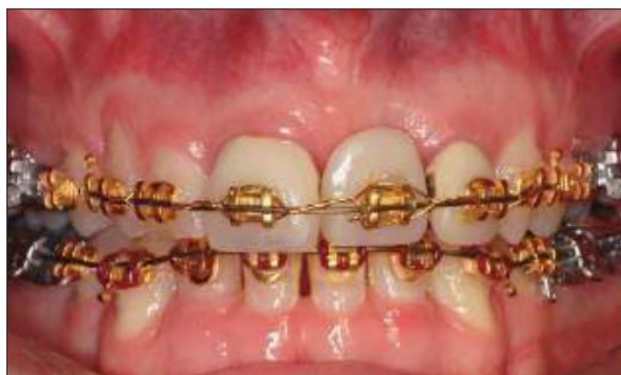

Fig 2 Retracted view of medium phenotype with inconsistent gingival margin positions and a buccal deficiency at the edentulous site.

A healthy 37-year-old female patient was referred for a consultation on the replacement of missing tooth 21 with an implant-supported restoration (Fig 1).

She stated that several years previously the tooth had been traumatically avulsed following a motor vehicle accident. The tooth was replaced with a three-unit fixed partial denture (FPD) immediately afterwards. Over time, she became disillusioned with the FPD and looked for a different option, including orthodontic therapy. She presented still in her orthodontic appliances, with the pontic sectioned free from the FPD but attached to the archwire. Her orthodontist felt that orthodontic treatment had been successfully completed, but nevertheless referred her before removing the appliances in case adjustments were necessary.

A detailed examination of the teeth and periodontium at and around the edentulous space was performed to assess the esthetic risk of implant therapy. The retracted anterior view revealed a mutually protected occlusion, approximately 25% overbite, and a slight midline deviation between the maxillary and mandibular arches (Fig 2).

The observed gingival phenotype was medium-thick, with moderately scalloped papillae, relatively thick tissue, a broad zone of keratinized gingiva, as well as teeth and crowns with a squared-off appearance. The periodontal examination revealed a healthy periodontium with probing depths between 1 to 3 mm throughout the sextant. A buccal bone and soft-tissue volume deficiency was visible at site 21, and there existed a lack of harmonious gingival margin positions in the anterior segment 13 to 23. Measurements of teeth 13, 12 and 22 revealed a 1 : 1 height-to-width ratio, while 13 and 23 displayed an ideal 1.2 : 1 height-to-width ratio.

A cone-beam computed tomography (CBCT) scan was ordered and evaluated. No pathology was noted. The evaluation of the scan included virtual implant placement that revealed adequate bone for implant placement (Fig 3).

However, a cross-sectional view at the root level revealed a buccal deficiency that could have compromised the esthetic outcome of the case, as it relates to recreating the ideal root eminence and emergence profile (Fig 4). This confirmed what was observed clinically at the initial examination.

Following the initial examination and CBCT scan, the collected clinical and radiographic data resulted in the Esthetic Risk Assessment (ERA) presented in Table 1.

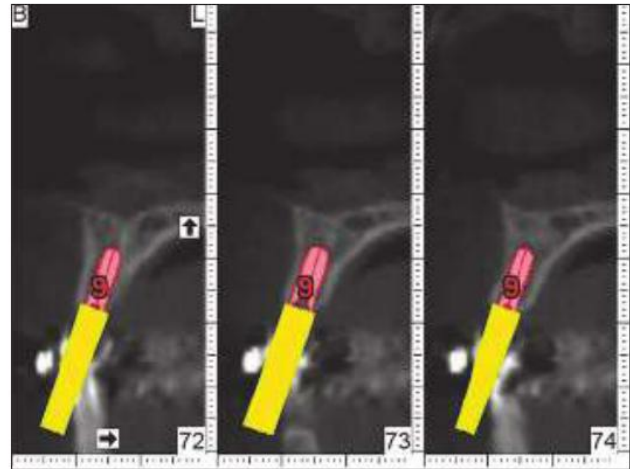


Fig 3 CBCT image with virtual implant placement showing adequate buccolingual bone volume for implant placement.

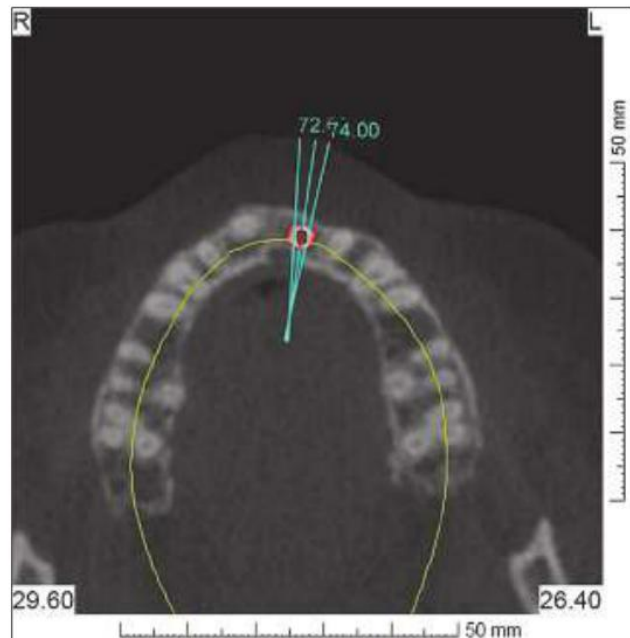


Fig 4 CBCT cross-sectional image revealed a slight but significant buccal deficiency at the edentulous site.

Table 1 Esthetic Risk Assessment (ERA)

Esthetic risk factors	Level of risk		
	Low	Medium	High
Medical status	Healthy, uneventful healing		Compromised healing
Smoking habit	Non-smoker	Light smoker (≤ 10 cigs/day)	Heavy smoker (> 10 cigs/day)
Gingival display at full smile	Low	Medium	High
Width of edentulous span	1 tooth (≥ 7 mm) ¹ 1 tooth (≥ 6 mm) ²	1 tooth (< 7 mm) ¹ 1 tooth (< 6 mm) ²	2 teeth or more
Shape of tooth crowns	Rectangular		Triangular
Restorative status of neighboring teeth	Virgin		Restored
Gingival phenotype	Low-scalloped, thick	Medium-scalloped, medium-thick	High-scalloped, thin
Infection at implant site	None	Chronic	Acute
Soft-tissue anatomy	Soft tissue intact		Soft-tissue defects
Bone level at adjacent teeth	≤ 5 mm to contact point	5.5 to 6.5 mm to contact point	≥ 7 mm to contact point
Facial bone-wall phenotype*	Thick-wall phenotype ≥ 1 mm thickness		Thin-wall phenotype < 1 mm thickness
Bone anatomy of alveolar crest	No bone deficiency	Horizontal bone deficiency	Vertical bone deficiency
Patient's esthetic expectations	Realistic expectations		Unrealistic expectations

* If three-dimensional imaging is available with the tooth in place

¹ Standard-diameter implant, regular connection

² Narrow-diameter implant, narrow connection

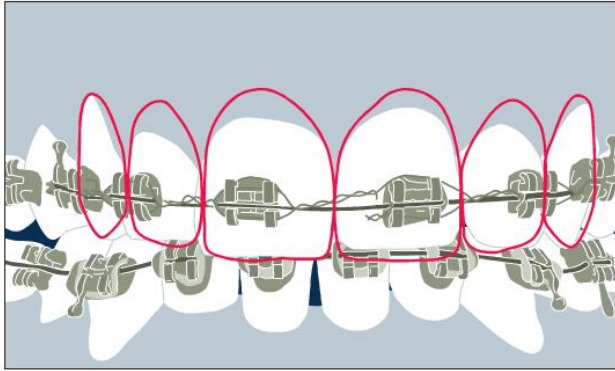


Fig 5 The crown dimension outlines illustrate the desired treatment outcome.

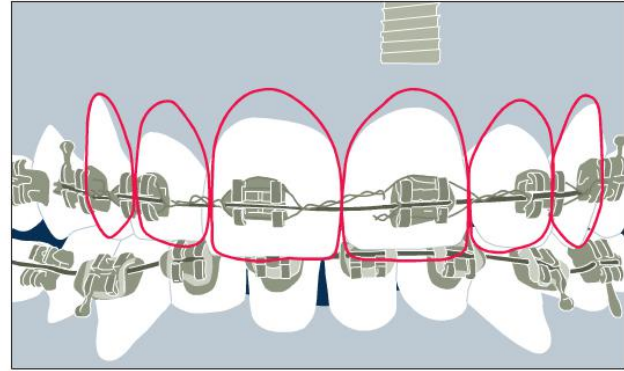


Fig 6 With the treatment illustration as a guide, the implant shoulder could be positioned 3 to 3.5 mm apical to the desired gingival margin.

The patient was presented with several restorative options to replace tooth 21, including replacement of her previous fixed partial denture with a new FPD. In this type of situation, where the abutment teeth require new full-coverage restorations, a fixed partial denture is a reasonable alternative. However, given the patient's previous disappointing experience with her FPD, an implant-supported restoration was her first and only choice. Taking into account all of the factors compiled in the clinical and radiographic examinations and the Esthetic Risk Assessment, as well as the successful completion of her orthodontic treatment, the overall esthetic risk for this patient was considered to be medium. In accordance with the ITI SAC Guidelines (Dawson and Chen 2009), the patient's treatment was classified as Advanced from both a surgical and restorative standpoint.

A comprehensive treatment plan was presented to the patient consisting of implant placement with hard- and soft-tissue augmentation for added buccal contour at site 21, and crown lengthening of teeth 12, 11 and 22. The illustration shows the expected final position of the gingival margins for the entire anterior segment at the completion of treatment (Fig 5).

It was discussed with the patient that crown lengthening would be critical to creating an acceptable esthetic outcome. Furthermore, it was considered essential that she understand that the desired final gingival margin position guides the apicocoronal positioning of the implant. The illustration shows the ideal apicocoronal implant position, allowing 3 to 3.5 mm of distance from the implant shoulder to the desired gingival margin (Fig 6).

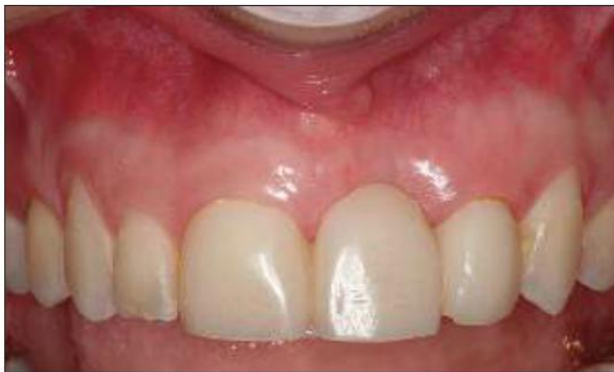

Fig 7 An acrylic FPD was placed as a provisional following removal of the orthodontic appliance. The pontic was fabricated to the desired final clinical dimensions.

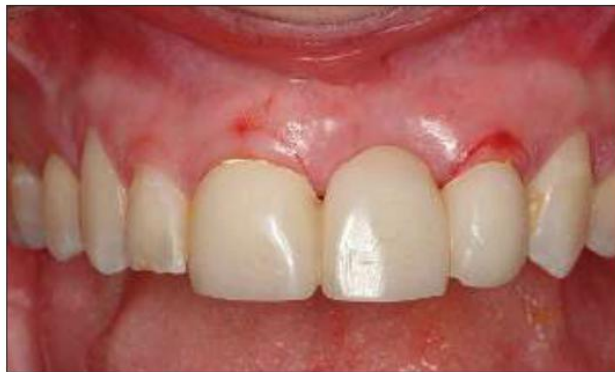

Fig 8 The desired gingival-margin positions were outlined.

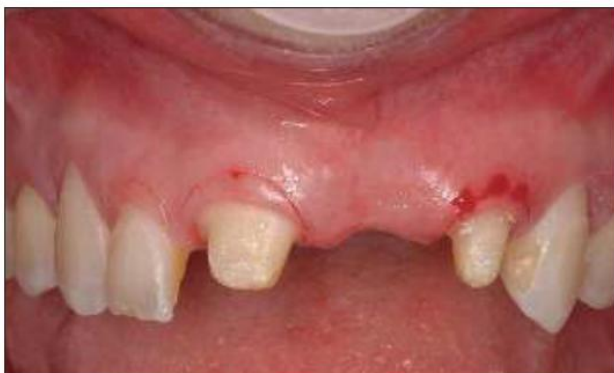

Fig 9 The provisional FPD was removed to allow completion of the incisions and flap elevation.

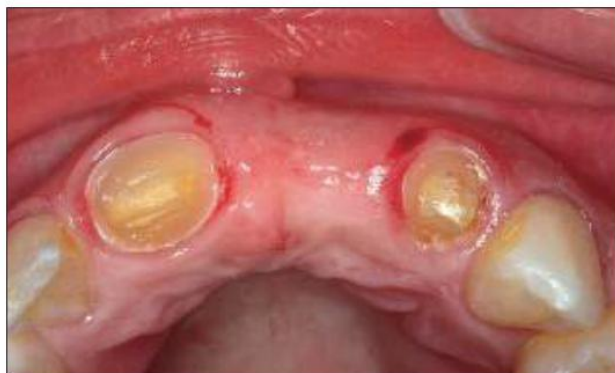

Fig 10 Occlusal view of the surgical site showing the deficient buccal contour.

With the treatment plan in place, the orthodontic appliances were removed and a fixed provisional was fabricated by the patient's prosthodontist. The pontic was made to reflect the desired dimensions of the final restoration in order to help guide the final implant position as well as the crown-lengthening procedures on teeth 12, 11, and 21 (Fig 7).

The first step in the surgical procedure was to outline the proposed clinical crown height (Fig 8). The contours were designed to create symmetry throughout the anterior segment. The provisional was removed to allow visualization of the surgical site and completion of the incision (Fig 9). The occlusal view demonstrates the deficiency in buccal contour that could compromise the final esthetic result (Fig 10).

Following flap reflection, the provisional was seated once more to properly evaluate the bone volume and position in relation to the desired implant shoulder position (Fig 11).

The overabundance of bone shown here would have complicated the ideal placement of the implant in relation to the desired emergence profile. 3 to 3.5 mm of space is needed to properly develop the necessary emergence profile. Crown lengthening was performed first on teeth 12, 11, and 22 using rotary and hand instrumentation (Fig 12).

This created the ideal biologic width around the teeth. Osseous recontouring was then accomplished at site 21 to create space for the correct implant depth and mimic the biologic width in the rest of the anterior sextant. The resulting osseous contour not only allows for the proper apicocoronal implant shoulder placement, but also more accurately reflects the natural contours of the alveolar bone around the teeth. Note that the bone at the mesial aspect of teeth 11 and 12 was left intact in order to properly support the interdental papillae.

To further facilitate ideal three-dimensional implant placement in accordance with the prosthodontic plan, a vacuform surgical template was utilized for site preparation (Figs 13 and 14).

In situations where significant modifications have to be made to the recipient site, a surgical guide provides a helpful reference point for correct fixture placement. The template provided guidance in both the orofacial and apicocoronal position, ensuring adequate space for development of the future emergence profile.

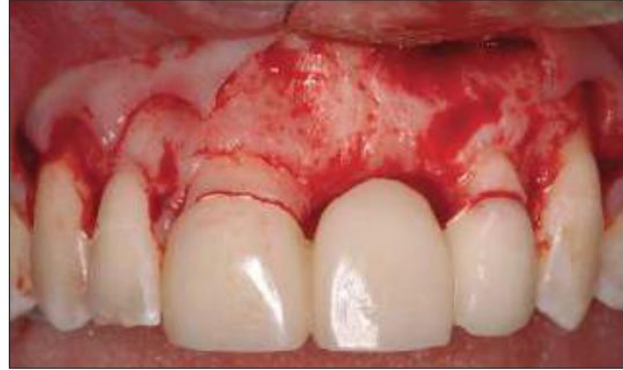

Fig 11 The provisional in place after flap reflection demonstrated an overabundance of bone, given the desired apicocoronal implant position.

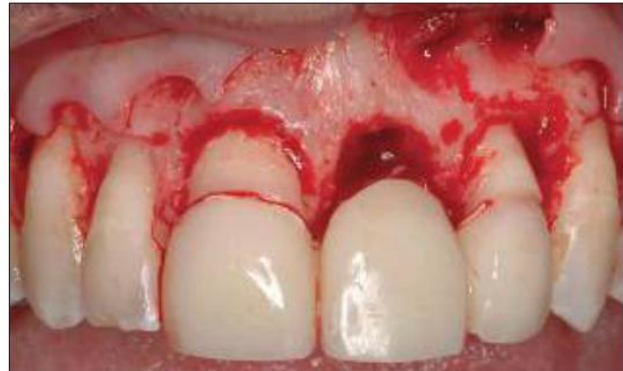

Fig 12 Crown lengthening was performed on teeth 12, 11 and 22. The osseous contour at site 21 mimics the contour of the natural dentition.

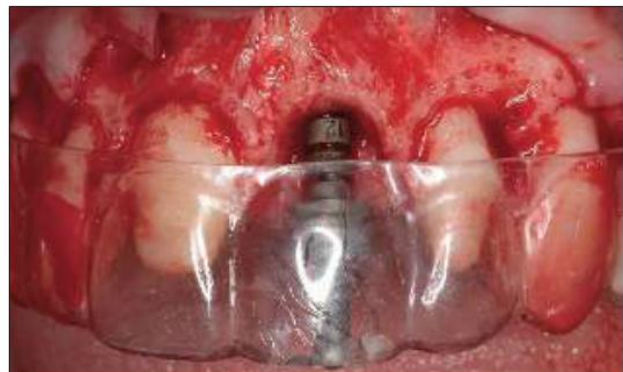

Fig 13 The vacuform template and 2.8-mm diameter depth gauge from the buccal aspect.

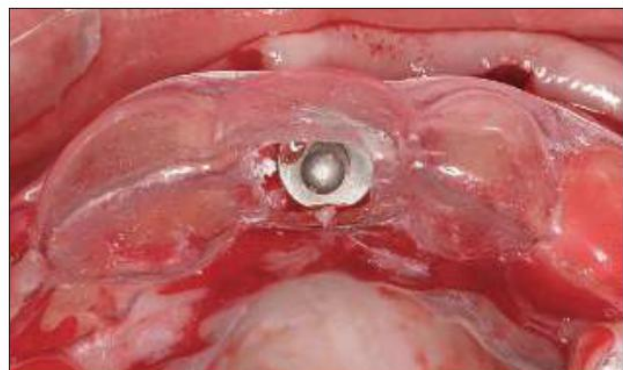

Fig 14 View of the vacuform template and 2.8-mm diameter depth gauge from the occlusal aspect.

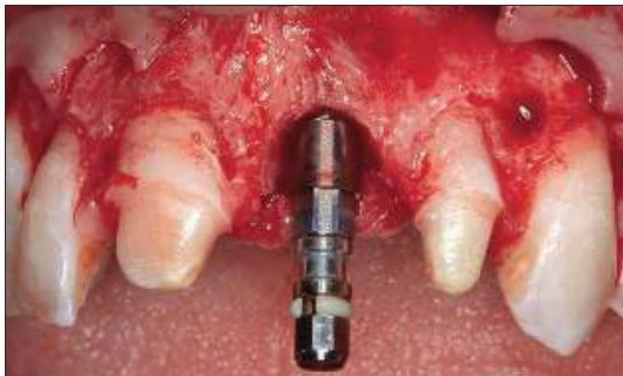

Fig 15 Bone Level implant in position.

Upon completion of site preparation, the implant (Bone Level implant, diameter 4.1 mm, length 12 mm, Regular CrossFit SLActive; Institut Straumann AG, Basel, Switzerland) was shown in its ideal three-dimensional position, in accordance with the restorative plan (Fig 15).

The occlusal view of the final implant position showed the implant fully enveloped within the native bone (Fig 16).

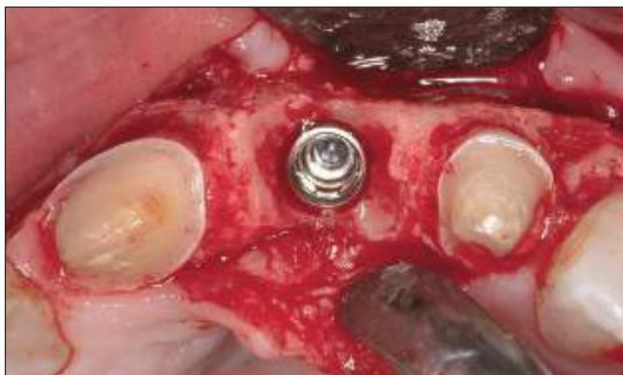

Fig 16 Occlusal view of the Bone Level implant. It is encased in native bone, yet a buccal defect remains.

However, a buccal defect remained, as previously observed in the CBCT scan. This defect could compromise the final esthetic result if not augmented to more closely resemble the contours of the natural dentition.

Following placement of a healing cap (Bone Level Regular CrossFit, height 2 mm; Institut Straumann AG), a xenograft derived from bovine hydroxyapatite (Bio-Oss, Geistlich, Wolhusen, Switzerland) was placed on the buccal aspect of the socket and covered with an autologous connective-tissue graft harvested with palatal periosteum using a single-incision palatal harvest technique (Lorenzana and Allen 2000) (Fig 17).

The tissue graft was secured with 5-0 chromic gut suture (Ethicon, Pittsburg, PA, USA) coronally and apically over the xenograft.

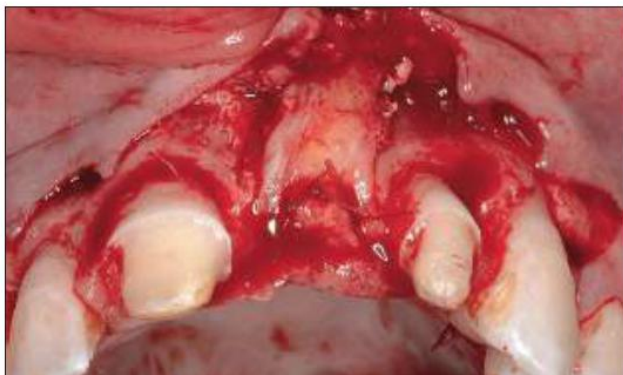

Fig 17 The buccal defect was augmented with deproteinized bovine bone mineral and a connective-tissue graft.

Flap closure was accomplished using 6-0 nylon suture (Ethilon; Ethicon) (Fig 18). The flap was reapproximated and sutured first at the papillae, followed by a horizontal mattress suture to relieve the tension in the flap. Interrupted sutures were placed to then obtain primary closure of the flap over the implant.

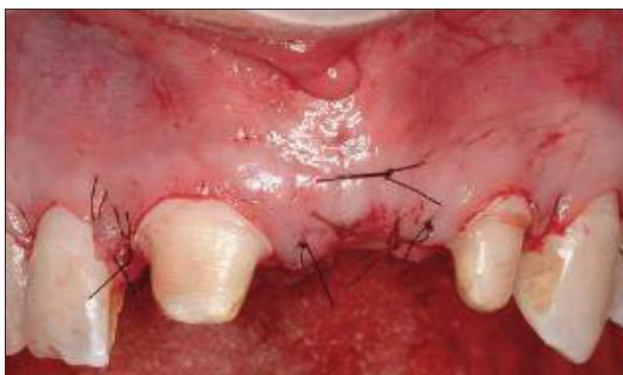

Fig 18 Tension-free primary closure was obtained with a horizontal mattress suture and single interrupted sutures.

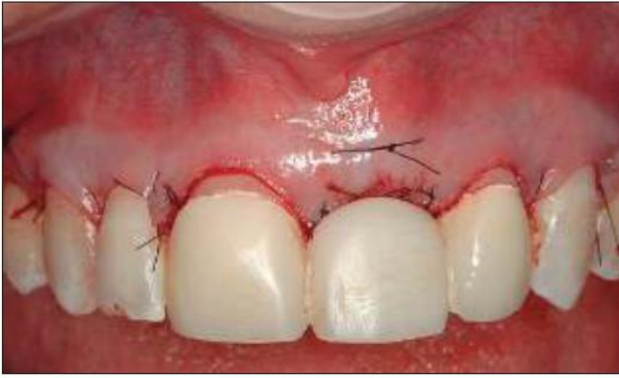

Fig 19 The provisional was adapted prior to cementation in order not to impinge upon the surgical site.

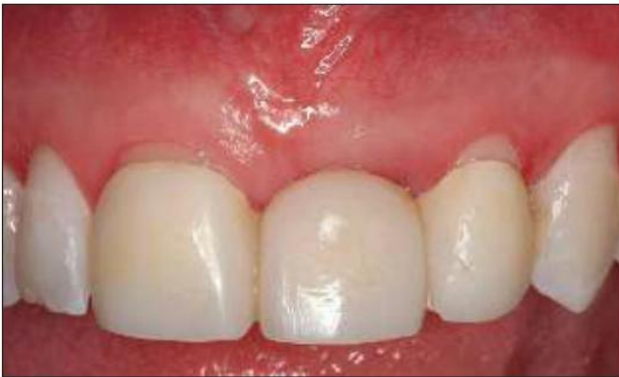

Fig 21 Healing at seven weeks. Re-entry procedures were initiated at this appointment.

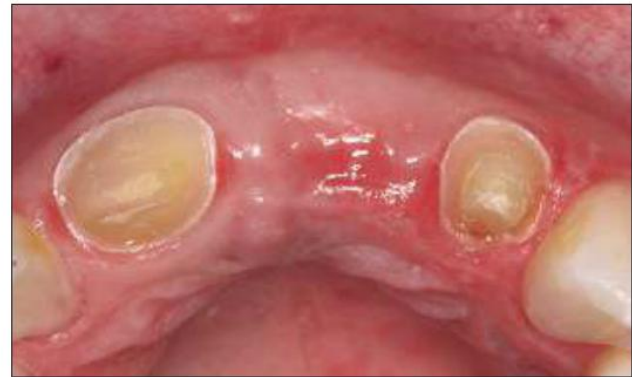

Fig 22 Following removal of the provisional, the occlusal view showed abundant soft-tissue volume and keratinized mucosa.

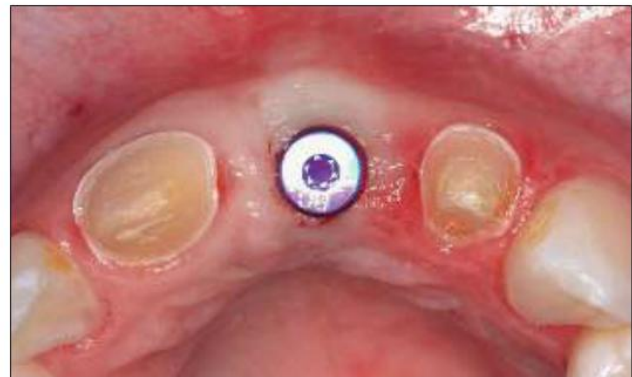

Fig 23 The uncovering was accomplished with a tissue punch. A longer healing cap was placed to allow access to the implant and initiate soft-tissue profile development.

Prior to re-cementing the provisional, the pontic was relieved over the implant site so as not to impinge on the tissues (Fig 19). A periapical radiograph was taken to document the final implant position (Fig 20).

The patient was seen two weeks after surgery for suture removal. Following an uneventful post-operative healing period of seven weeks, the patient was scheduled for re-entry (Fig 21).

Due to the volume of tissue available at the implant site following augmentation, as well as the more than adequate amount of keratinized gingiva present, the implant was uncovered utilizing a tissue punch (Figs 22 and 23). The smaller healing cap was replaced with a longer healing cap to begin the development of the peri-implant soft-tissue profile. Healing was uneventful; four weeks later, the patient was referred to her prosthodontist for the initiation of restorative procedures.

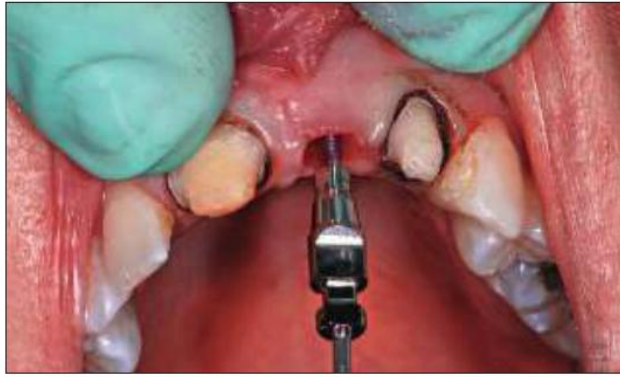

Fig 24 Delivery of the RC impression post.

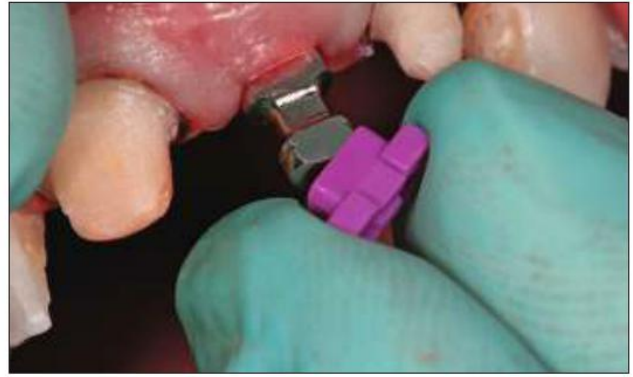


Fig 25 Placement of the polymer impression cap on the impression post.

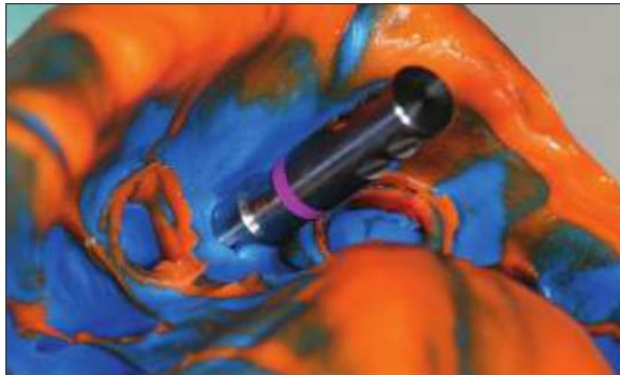


Fig 26 Following the removal of the impression post, it is placed onto the analog and placed back into the impression. The impression can now be poured to fabricate the master cast.



Fig 27 The Bone Level Regular CrossFit (RC) temporary abutment.

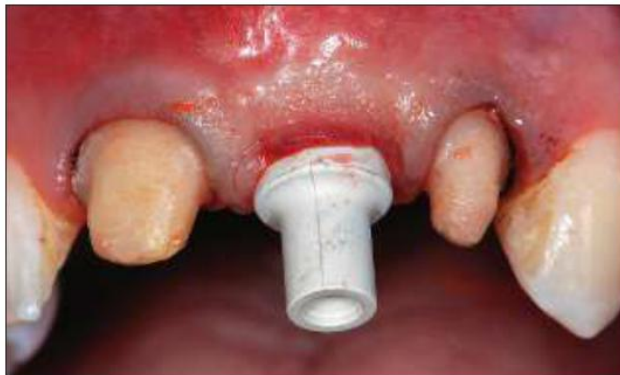

Fig 28 The unmodified temporary abutment is tried in and marked for reduction.

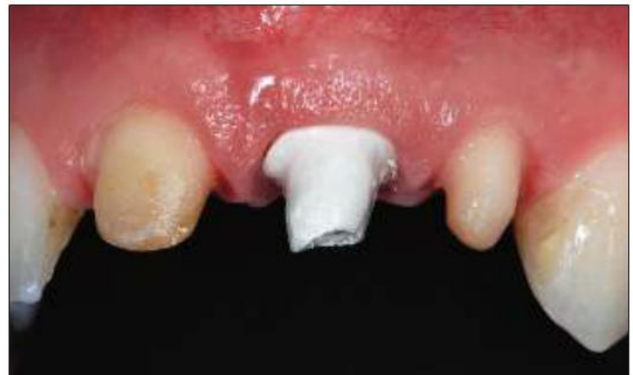

Fig 29 The modified temporary abutment fully seated.

First, a fixture-level impression was taken along with the adjoining preparations by placing a Regular CrossFit (RC) impression post into the implant and tightening the guide screw with an SCS screwdriver (Fig 24). The polymer impression cap was then placed on the impression post and the impression taken (Fig 25). After the impression had set and been removed, the polymer cap remained in the impression. The impression post was removed, attached to a Regular CrossFit analog, and repositioned in the impression tray prior to pouring it in stone (Fig 26).

At this point, the master cast was stored until the peri-implant tissues could be shaped and conditioned with the provisional restoration. Development of the emergence profile began with the modification of a Bone Level Regular CrossFit (RC) temporary abutment (Fig 27). After removal of the healing cap, the unmodified temporary abutment was seated and marked for reduction (Fig 28).

Following reduction, the temporary abutment was seated by turning the screw slowly, allowing time for the tissue to adjust to the pressure exerted by the abutment, until fully seated (Fig 29).

The patient wore the provisional for approximately four weeks until she was satisfied with the soft-tissue contours and overall esthetics (Fig 30). At this point, it was important to transfer the patient's soft-tissue contours to the master cast prior to sending the case to the laboratory. The provisional and temporary abutment were removed. The resulting emergence profile closely mimicked that of the contralateral tooth (Fig 31).

The original soft-tissue model was removed and the temporary abutment placed on the master cast (Fig 32).

Petroleum jelly was applied to the temporary abutment, and the new soft-tissue model was created by applying and forming impression material around the temporary abutment (Figs 33 and 34). The temporary abutment and provisional crown were then repositioned in the patient's mouth, and the case was sent to the laboratory.

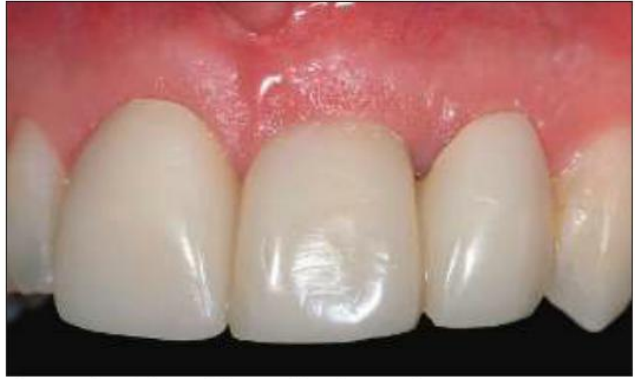

Fig 30 After delivery of the provisional restoration.

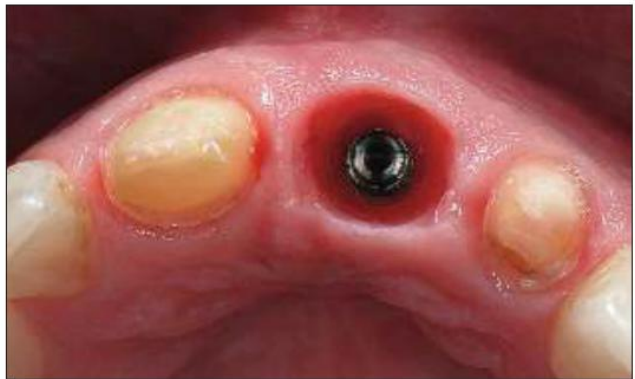

Fig 31 Occlusal view of the peri-implant tissue contours after development of the transition zone. Close similarity to the tissue contours around the contralateral central incisor.

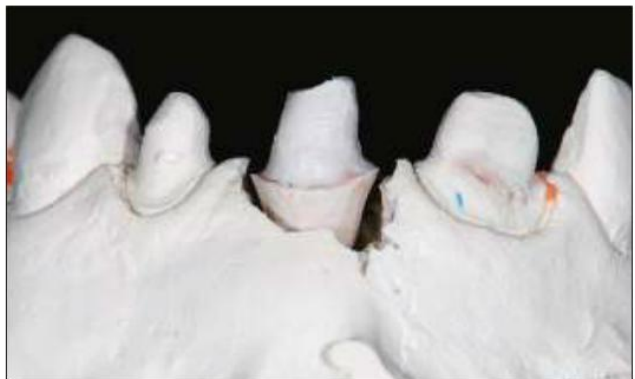

Fig 32 The provisional abutment seated on the master cast before custom soft-tissue modeling.

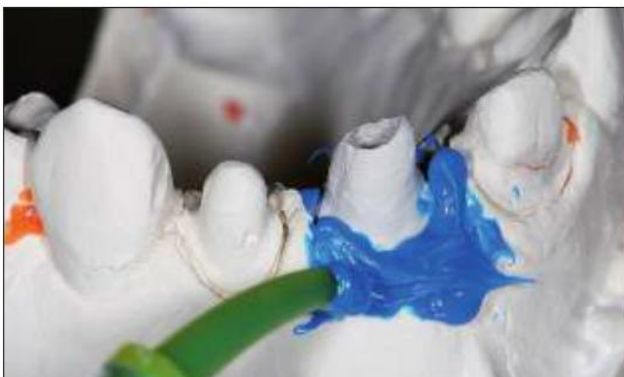

Fig 33 Impression material applied around the provisional abutment to record the transition zone onto the master cast.

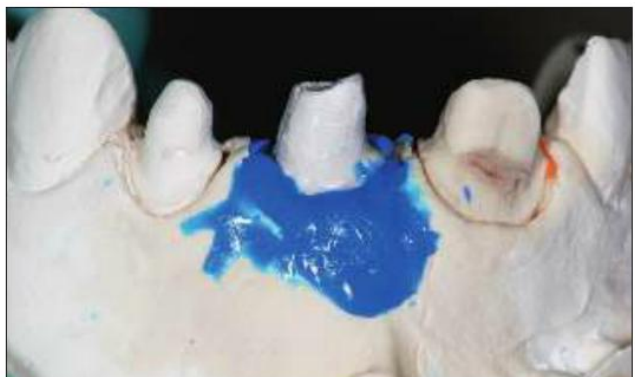

Fig 34 The custom soft-tissue model was now complete and the master cast ready to be delivered to the laboratory.



Fig 35 The definitive zirconia abutment and crown.

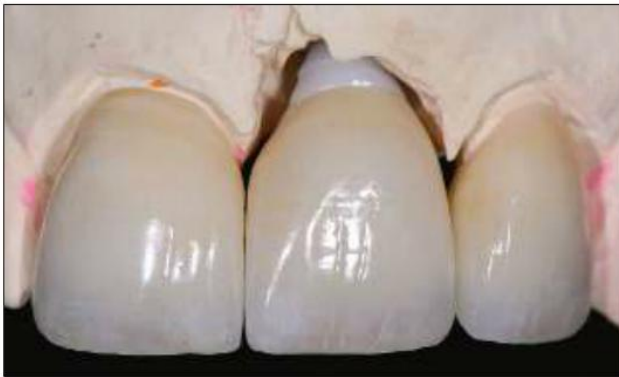

Fig 36 The definitive all-ceramic crowns on the master cast.

The laboratory fabricated a CAD/CAM zirconia abutment, made by first waxing up the abutment contours, then scanning the wax-up for milling of the final abutment. Once completed, an all-ceramic crown was made by building up ceramics over a zirconia core (Fig 35). Two additional crowns were fabricated for teeth 11 and 22 (Fig 36). The custom abutment and crown were returned for final delivery to the patient.

At the delivery visit, the provisional restoration and abutment were removed. The implant and soft tissues were carefully cleaned and irrigated before delivery of the tooth-borne crowns and the custom abutment (Fig 37).

In addition, composite was bonded to tooth 12 in order to restore the contours to match those of tooth 22. Once the fit had been confirmed, the abutment was torqued to 35 N-cm, and the access opening sealed with PTFE tape and composite.

The fit of the final restoration was carefully checked and the occlusion adjusted to a light contact as verified with shimstock prior to cementation. The restoration was cemented, and any excess was carefully removed following the final set (Fig 38). On the day of delivery, the shape, color, contour, and translucency of the restorations appeared to integrate harmoniously with the natural dentition. However, it was evident that following the restorative procedures, additional tissue healing and maturation was necessary prior to achieving the desired final esthetic result.

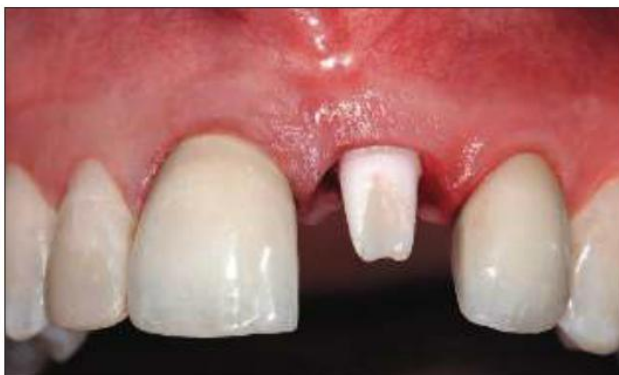

Fig 37 After insertion of the zirconia abutment, torqued to 35 N-cm and sealed with PTFE tape and composite.

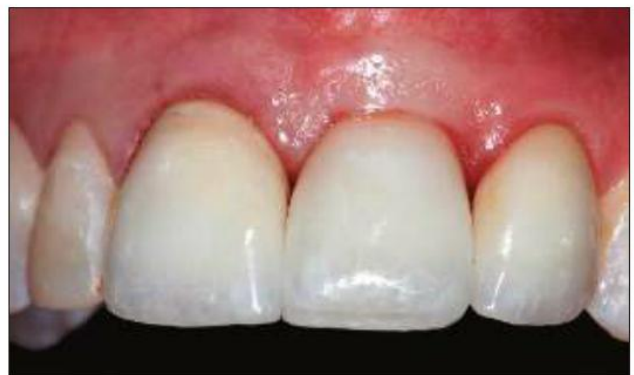

Fig 38 The final implant-supported restoration on the day of delivery.

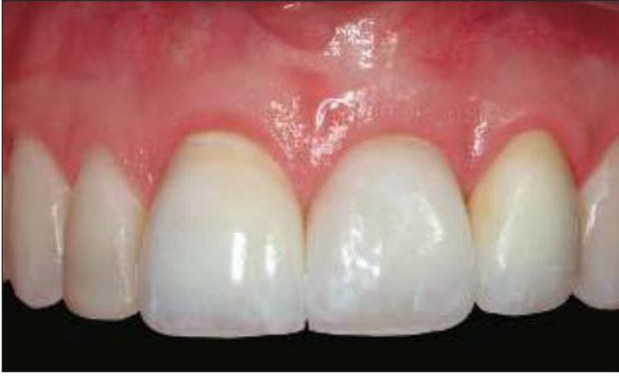

Fig 39 Retracted anterior view at one year after delivery. Symmetric gingival contours in harmony with the restorations across the anterior sextant.

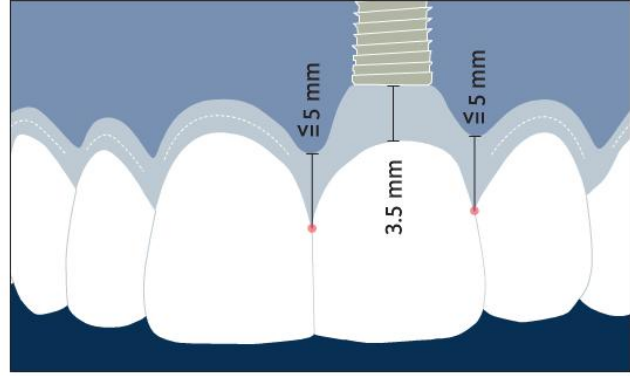


Fig 40 A stable soft-tissue level could be expected due to the ideal relationship between the bone crest, implant shoulder and contact points.

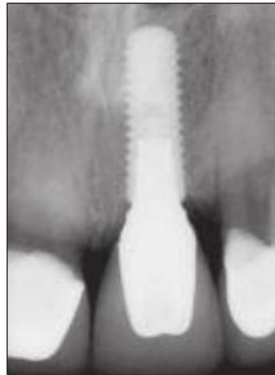

Fig 41 Periapical radiograph at one year.

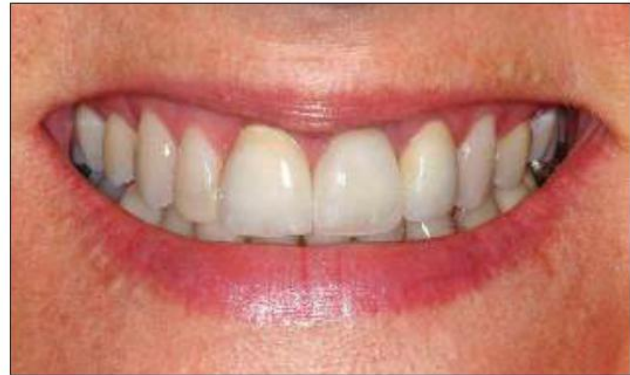

Fig 42 Full smile at one year after delivery, demonstrating a stable, pleasing esthetic result.

The one-year photograph documents the final harmonious perio-prosthetic integration of the restorations and the gingival tissues that comprises a stable esthetic treatment outcome (Fig 39).

The contours of the marginal gingiva were symmetrical throughout the anterior sextant and in concert with the restorative contours of the restorations and natural dentition. The papillae completely filled the interdental spaces, a testament to the pre-operative planning of the apicocoronal implant position and surgical execution of the necessary osseous recontouring (Fig 40).

The one-year postoperative radiograph demonstrated stable bone levels around the implant, with the appropriate interdental bone position in relation to the interdental contacts that supported the papillae at the mesial and distal aspects of the implant fixture (Fig 41).

Finally, the one-year smile reflected the realization of the patient's vision and her satisfaction with the final esthetic result (Fig 42).

Acknowledgments

Orthodontic procedures

Dr. Brad D. Bruchmiller, South Texas Orthodontics – San Antonio, TX, USA

Laboratory procedures

Nuance Dental Ceramics, Inc. – Mansfield, TX, USA