

Esthetic Management of Multiple Recession Defects in a Patient With Cicatricial Pemphigoid

Eduardo R. Lorenzana,* Terry D. Rees,† and William W. Hallmon‡

Cicatricial pemphigoid is one of a number of mucocutaneous disorders that can present in the oral cavity with desquamation, pain, and bleeding of the gingiva and oral mucosa. This case report describes the management of cicatricial pemphigoid in a patient with multiple sites of gingival recession using connective tissue grafting to alleviate root surface sensitivity and improve esthetics. The treatment rationale is presented and discussed in terms of timing of therapy and implications for wound healing in patients who present with desquamative gingivitis. J Periodontol 2001;72:230-237.

KEY WORDS

Corticosteroids/therapeutic use; gingivitis, desquamative; grafts, connective tissue; mucous membrane/surgery; pemphigoid, benign mucous membrane; periodontal diseases/therapy.

Cicatricial or mucous membrane pemphigoid is a mucocutaneous disorder of unknown etiology which can affect the oral cavity,¹ eyes,^{2,3} respiratory mucosa,⁴ and genitalia.⁵ Diagnosis is dependent on clinical presentation as well as histopathologic and immunofluorescence studies. Clinically, cicatricial pemphigoid is more common in women by a ratio of 3:1, with a mean age of onset of 56 years for women and 63 years for men.⁶ Intraorally, it primarily affects the attached gingiva, followed by the buccal mucosa, palate, tongue, and oropharynx.⁶

Cicatricial pemphigoid is characterized histologically by a “sub-basilar split,” in which the epithelium remains intact but is separated from the underlying connective tissue within the basal lamina. A non-specific inflammatory infiltrate is present in the lamina propria consisting of neutrophils, lymphocytes, macrophages, and occasional plasma cells.⁷ Direct immunofluorescence reveals deposits of IgG and C3 along the basement membrane zone, creating a linear pattern of fluorescence which is diagnostic for this condition.⁸⁻¹⁰

Once a definitive diagnosis is determined, treatment is focused upon the alleviation of clinical signs and symptoms, referral for consultation with other specialists to assess the extent of the disease process, and the prevention of recurrence.¹¹ Although there is no consensus in the literature as to the appropriate mode of therapy for intraoral cicatricial pemphigoid lesions,¹¹ initial treatment usually includes the use of topical corticosteroid agents.^{12,13} Refractory cases may require systemic steroid administration, dapsone, or other immunosuppressant agents either alone or in combination with topical agents.⁶

Patients with desquamative lesions often present with periodontal and dental problems in addition to painful, erosive gingiva; however, little information exists regarding the dental and periodontal management of patients with concurrent mucocutaneous diseases and periodontal destruction.¹⁴⁻¹⁶ This report describes the management of a patient with multiple sites of gingival recession and tooth hypersensitivity complicated by the presence of cicatricial pemphigoid. Pharmacologic and surgical treatment regimens are discussed along with the treatment ra-

* Department of Periodontics, Baylor College of Dentistry—TAMUS, Dallas, TX; private practice, San Antonio, TX.

† Department of Periodontics, Baylor College of Dentistry—TAMUS.

‡ Graduate Periodontics.

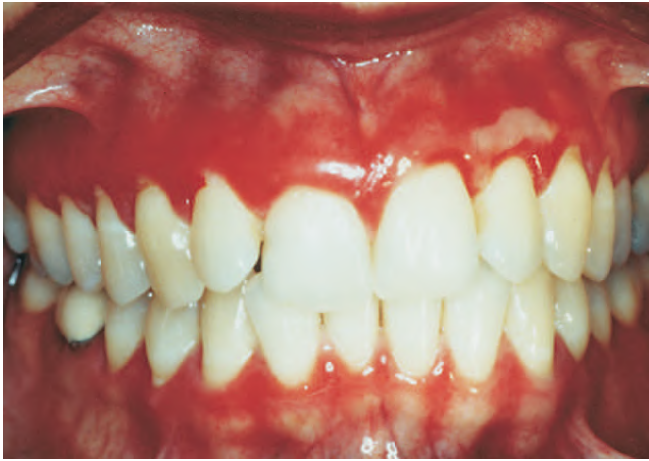

Figure 1.

Initial presentation with diffuse erythema throughout the attached gingiva, sloughing epithelium in the area of #10, and multiple recessions.

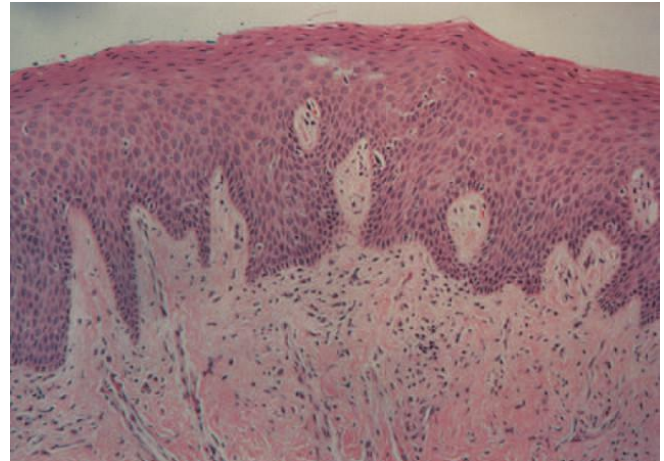


Figure 2.

Histopathologic specimen (original magnification $\times 10$). Note that at this magnification power, no separation is evident between the epithelium and underlying connective tissue. It is possible that electron microscopy would have revealed a separation between the epithelial lamina and the lamina propria, but that procedure was not performed.

tionale, possible complications, and wound healing implications.

CASE REPORT

A 41-year-old Latin American female was referred to the Stomatology Center in the Baylor College of Dentistry–Texas A & M University System (TAMUS) Health Science Center, Department of Periodontics with a 1-year history of painful, ulcerated gingiva and multiple gingival recessions (Fig. 1). A review of her medical history revealed controlled hypertension, as well as a past history of frequent migraine headaches and depression. Her medications included a trandolapril-verapamil combination and sumatriptan succinate.

The initial examination revealed diffuse erythema, bleeding, and sloughing gingiva consistent with desquamative gingivitis. Teeth #6, 11, 12, and 21 presented with Miller Class I recessions that were exquisitely sensitive to thermal stimulation and were of significant esthetic concern to the patient. The patient's oral hygiene, although quite effective, was hampered by her gingival condition. A gingival biopsy was obtained from the interproximal area of teeth #12 and 13 and submitted for routine histopathology and direct immunofluorescence (DIF). The patient received oral hygiene instructions consisting of gentle gingival debridement and the use of a 0.12% chlorhexidine gluconate antimicrobial mouthrinse. Careful instrumentation was performed to eliminate supragingival plaque-induced inflammation.

Histologic examination revealed stratified squa-

mous epithelium exhibiting a parakeratinized surface and a normal maturation pattern. A mild chronic inflammatory cell infiltrate consisting of lymphocytes and plasma cells was noted within the underlying fibrous tissue; however, there was no evidence of a subepithelial separation to confirm the diagnosis of pemphigoid (Fig. 2).

DIF testing was performed using conjugates for IgG, IgA, IgM, C3, C4, and fibrinogen. The patient's tissue tested positive for IgG and C3, with linear staining at the mucosal-submucosal junction (Fig. 3). These findings confirmed cicatricial pemphigoid. The patient was prescribed a high-potency topical corticosteroid, fluocinonide 0.05% gel, to be applied 3 times daily, and referred to an ophthalmologist for evaluation. No ocular involvement was detected. After 3 months with only limited clinical response, the medication was changed to an ultra-high potency topical steroid, betamethasone dipropionate 0.05% gel, again applied 3 times daily. The patient was monitored periodically for oral *Candida* infection while on topical steroid treatment. Following 1 more month of treatment, the patient's lesions were eliminated, and no new lesions developed. After 1 additional month with no recurrence, the condition was deemed to be in remission and the patient was appointed for surgery.

Examination of teeth #6, 11, 12, and 21 revealed 3 mm recessions, minimal probing depths, and approximately 2 to 3 mm of attached gingiva apical

Case Report

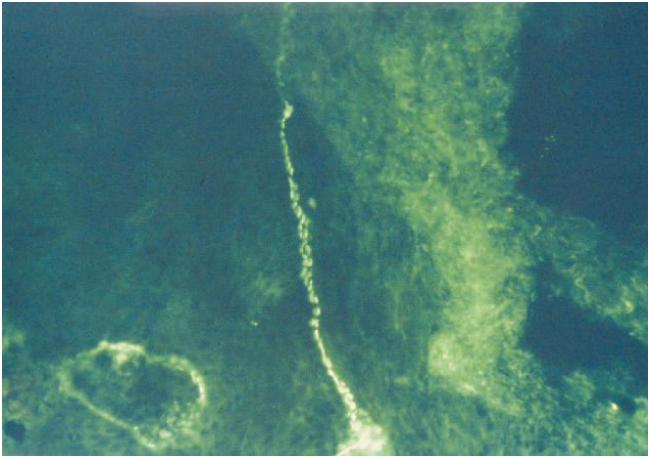


Figure 3. Direct immunofluorescence. 3+ linear IgG staining and 4+ linear C3 staining at the mucosal-submucosal junction.

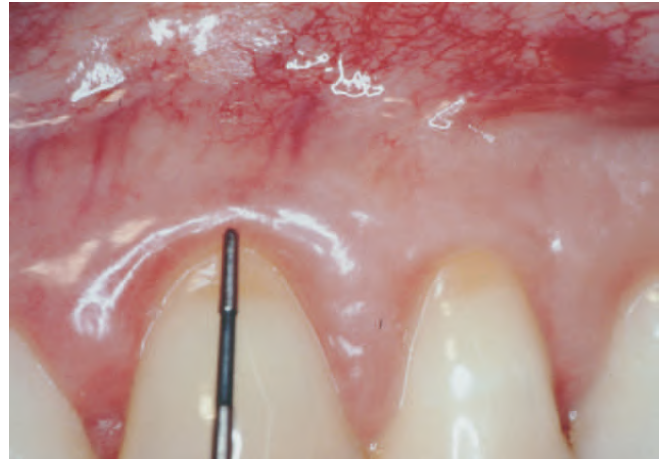


Figure 4. Three mm Miller Class I recessions on teeth #11 and 12 at the time of surgery.

to the recessions (Fig. 4). The exposed root surfaces were carefully root planed and biomodified by bur-nishing with citric acid for 30 seconds. The recipient sites were prepared using an incision design previously described by Allen.¹⁷ Briefly, blocked incisions were used to denote the extent of coronal positioning of the flap (Fig. 5). A partial-thickness flap dissection was extended well into the vestibule to allow passive coronal positioning of the flap.

Following preparation of the recipient bed, the connective tissue graft was harvested using a single incision palatal harvest technique.¹⁸ Primary palatal flap adaptation was achieved and the donor site sutured using 5.0 chromic gut suture (Fig. 6). The graft was adapted to the recipient bed (Fig. 7) and the flap coronally positioned and secured, also with 5.0 chromic gut suture (Fig. 8). The subsequent healing period was uneventful following all surgeries, with no recurrence of gingival pemphigoid lesions. The patient continued on topical corticosteroid treatment throughout the surgical and healing phases of treatment.

With her condition controlled and in remission, the patient's topical steroid regimen was gradually decreased over time. Daily dosing was decreased from 3 times daily to twice daily applications of betamethasone dipropionate 0.05% gel. With continued remission, the patient was instructed to use the medication only if there was recurrence of the pemphigoid lesions.

After a follow-up period of 18 months, nearly 100% root coverage was evident with no inflammation, minimal probing depths, and favorable esthetics (Fig. 9).

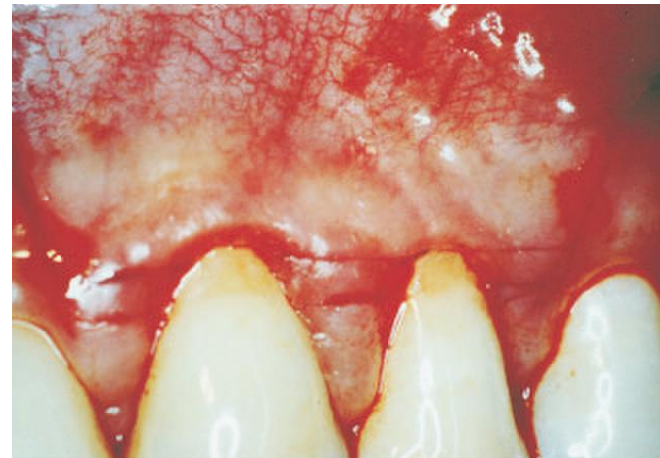


Figure 5. Blocked incision flap design of connective tissue graft recipient site.

During this time, there was only an occasional recurrence of erythema, particularly in the area of tooth #7, which was treated with betamethasone dipropionate 0.05% gel only as needed (Fig. 10). No erythema, pain, or ulceration has been associated with any of the grafted sites during the entire follow-up period. The patient is on a 6-month recall schedule in the Stomatology Center and on yearly recall with her ophthalmologist.

DISCUSSION

Cicatricial pemphigoid is a chronic mucocutaneous disorder that presents with erythema, vesicles, and

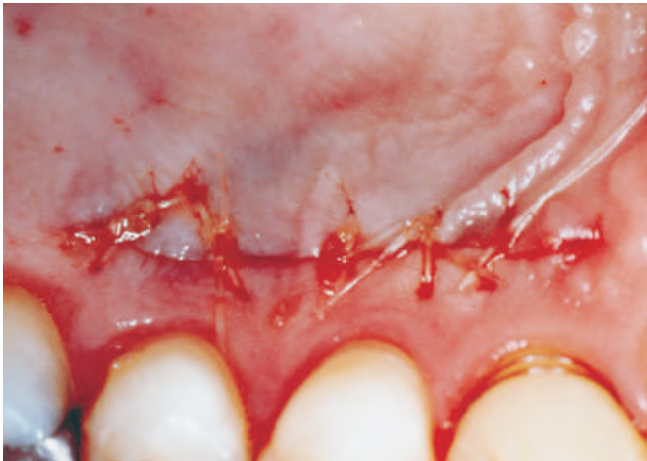

Figure 6.
Single incision palatal harvest of connective tissue graft donor site.

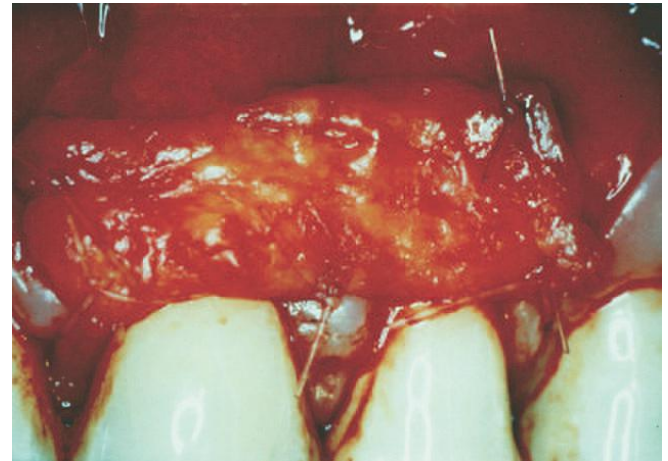


Figure 7.
Harvested connective tissue graft sutured in situ.

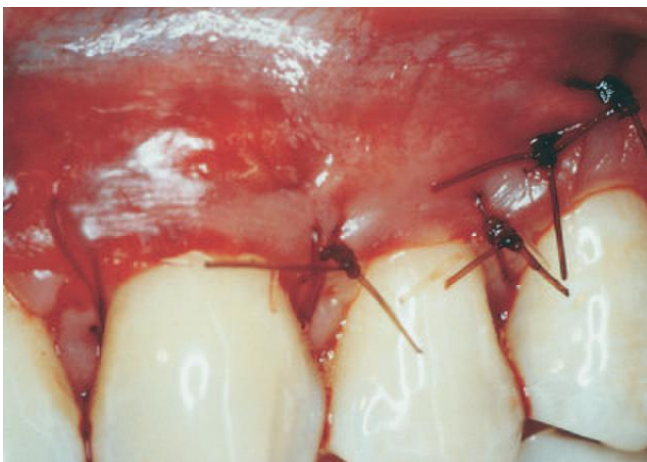

Figure 8.
Flap coronally positioned over connective tissue graft.

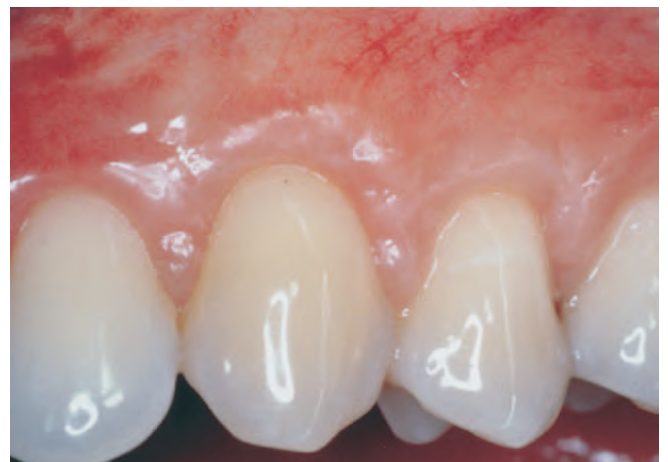

Figure 9.
100% root coverage at 18 months. Note healthy tissue contours and color.

ulcerations with sloughing, easily displaced surface epithelium, also known as Nikolsky's sign. Clinically, cicatricial pemphigoid is often indistinguishable from other vesiculobullous diseases such as erosive lichen planus, pemphigus vulgaris, linear IgA disease, lupus erythematosus, and chronic ulcerative stomatitis. It is not unusual for these conditions to be misdiagnosed as gingivitis, periodontitis, or acute necrotizing ulcerative periodontitis.¹⁹

Biopsy specimens of cicatricial pemphigoid usually show separation of the epithelium from the underlying connective tissue in what is often described as a sub-basilar split. Such histologic findings lead to a differential diagnosis of cicatricial or bullous pem-

phigoid, linear IgA disease, bullous lichen planus, erythema multiforme, epidermolysis bullosa acquisita, dermatitis herpetiformis, or herpes gestationis.^{6,11} As evidenced by this report, vesiculobullous conditions such as cicatricial pemphigoid do not always adhere to a typical histological presentation. Data from our Stomatology Center indicate that gingival cicatricial pemphigoid will sometimes present normal histologic features or a non-specific inflammatory response. This emphasizes the importance of direct immunofluorescence techniques in establishing a definitive diagnosis. The presence of linear deposition of IgG and C3 along the basement membrane is a univer-

Case Report

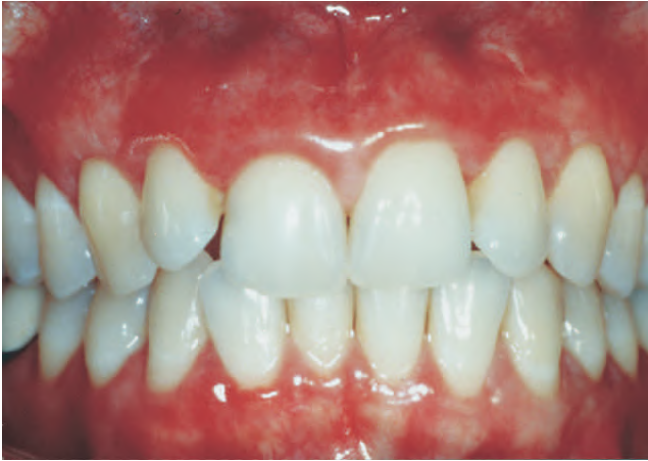

Figure 10.
Results at 18 months.

sally accepted finding in cicatricial pemphigoid,⁸ although IgM, IgA, and fibrinogen have also been observed.^{10,20}

Review of the literature has revealed no consensus as to the proper treatment regimens for patients with oral cicatricial pemphigoid.¹¹ Large-scale clinical trials are lacking, with most of the published literature consisting of case reports or case series. Therefore, treatment is generally directed towards controlling the patient's symptoms, eliminating inflammation caused by plaque or prosthetic devices, and eradicating gingival and mucosal lesions. It is not known whether treatment of asymptomatic lesions is necessary to prevent disease progression.²¹ Periodic oral and ophthalmologic examinations, however, are universal recommendations.²¹

This paper describes the successful treatment of multiple gingival recessions in a patient diagnosed with cicatricial pemphigoid. Management of the oral lesions was achieved using only topical corticosteroid treatment. Following elimination of the lesions, the patient's gingival recessions were treated using connective tissue grafts. Topical corticosteroid therapy was not discontinued at any time during the healing phase. The patient has remained free of pemphigoid-associated lesions for over 18 months and nearly 100% root coverage has been maintained.

The use of connective tissue grafts for the coverage of denuded root surfaces is well documented in the literature.²² However, this is the only known case of connective tissue grafting involving a mucocutaneous disorder and concomitant topical corticosteroid therapy. In fact, few articles address any type of peri-

odontal or prosthetic treatment in patients with mucocutaneous disorders. Chaikin used free soft tissue autografts (FSTA) to eliminate the affected buccal gingiva in a case of long-standing chronic desquamative gingivitis.¹⁴ The rationale for treatment stemmed from the inability to obtain control of the patient's symptoms with repeated systemic steroid administration. Therefore, the author successfully replaced the affected buccal gingiva with healthy palatal tissue and was able to alleviate the patient's symptoms. No definitive diagnosis was given, although histopathology revealed a separation between the epithelium and the underlying connective tissue, a finding consistent with cicatricial pemphigoid.

In a similar clinical and histologic case study, Pini Prato and coworkers eliminated lesions associated with oral lichen planus by using FSTA.¹⁵ In addition, they transplanted the lichen planus lesions to the donor palatal wound to attempt to initiate lichen planus in a previously uninvolved site. They found that an FSTA could eliminate lichen planus lesions and that these lesions could be transplanted to previously healthy sites. The authors concluded that the basal cells which are the target of the autoimmune response must be eradicated in order to prevent recurrence of erythema and ulceration.¹⁵

In contrast to the aforementioned reports, the grafting procedures described in the present paper were performed following elimination of the pemphigoid lesions for the purpose of covering denuded root surfaces. Connective tissue grafts have the advantage of bilaminar blood supply, a minimal palatal wound, an accelerated healing phase compared to FSTA, and superior esthetics.^{23,24} However, the surgeon must be able to manipulate the pedicle flap over the connective tissue graft. Active vesiculobullous lesions prevent manipulation of the pedicle flap due to sloughing tissue, inflammation, and lack of elasticity. Therefore, it is imperative that if connective tissue grafting is indicated in patients with desquamative conditions, the gingiva at the recipient site must be free of active desquamation over an extended period of time prior to entering into the surgical phase.

Brain and coworkers recently described connective tissue grafting for root coverage in a patient with dystrophic epidermolysis bullosa (EB).¹⁶ Dystrophic EB is characterized by blistering below the basement membrane within the dermis, causing a histologic split similar to that seen in cicatricial pemphigoid patients. Treatment for EB is palliative in nature, with

no known cure. Therefore, the authors were forced to perform surgery in less-than-optimal conditions. They found that manipulation of the epithelium associated with the surgical area was not possible due to sloughing following the slightest contact or suction. Following multiple procedures, however, the authors were successful in obtaining near-complete root coverage.

The use of topical corticosteroids is a potential complicating factor in the surgical management of these patients. The anti-inflammatory and immunosuppressant effects of topical corticosteroids may be detrimental to normal wound healing and directly related to the potency of the medication and the duration of treatment.²⁵ Corticosteroids can retard wound healing by causing morphological and functional changes in fibroblasts. This may result in reduced collagen synthesis and turnover, as well as inhibition of glycosaminoglycan production.²⁶⁻²⁸ Alteration of the enzymes involved in collagen synthesis and suppression of collagenase production have been reported.^{27,29}

Marks and coworkers found that a weak (hydrocortisone cream 1%) and medium strength (fluocinolone acetonide ointment 0.025%) topical steroid applied to full-thickness skin wounds in an animal model significantly retarded wound healing when compared to vehicles alone.³⁰ This was attributed not only to the aforementioned connective tissue alterations, but also to the impairment of epidermal regeneration,²⁶ mitotic activity,³¹ and DNA synthesis.^{32,33} Using a similar animal model, Nguyen and coworkers found that dexamethasone sodium phosphate, betamethasone sodium phosphate, and betamethasone sodium phosphate-acetate caused a 50% reduction in the total circulating white blood cells at the surgical wound site immediately after wounding.³⁴ This may be another mechanism by which topical steroid application can alter the normal wound healing process.

Thinning of the mucosa is another detrimental effect of long-term topical steroid use.³⁵ This may be due to a decrease in epidermal kinetic activity,³⁶ a decrease in keratinocyte thickness,³⁷ flattening of rete ridges,³⁸ reduced mitotic activity,³⁹ and reduced production of collagen and ground substance.^{40,41} This, in turn, may complicate preparation of the recipient bed for the connective tissue graft as well as pedicle flap manipulation. If surgery were to trigger recurrence of the pemphigoid lesions in a patient receiving a soft tissue graft, it would be important to assess the degree of post-surgical wound healing prior to increasing the frequency of administration of

the steroid or prior to upgrading to a more potent topical or systemic steroid treatment. Healing should be allowed to continue without additional steroid administration for at least 3 weeks to allow for graft revascularization and adaptation. Once the graft and wound are deemed stable, treatment to manage the lesions can be modified as required.

Betamethasone dipropionate gel is an ultra-high potency class of topical corticosteroid used in the treatment of mucosal diseases that are resistant to less potent topical medications. Although some reports suggest that the use of ultra-high potency topical corticosteroids can result in a detectable systemic uptake of the medication and potentially induce suppression of endogenous corticosteroid production, others have reported only minimal suppression of the hypothalamic-pituitary-adrenal axis.⁴² To date there are no reports of adrenal suppression, hypertension, or other untoward systemic effects following the topical use of these medications in the oral cavity.

Most research in this area is reported in the dermatology literature and pertains exclusively to extraoral applications. This does not take into account conditions found in the intraoral environment. Constant flushing of the oral cavity by saliva as well as movement of the lips, tongue, and buccal mucosa may prevent accumulation of the steroid on the gingiva and oral mucosa, thereby reducing the adverse effects previously noted in extraoral applications. Practitioners who are considering the use of the occlusive therapy (i.e., plastic stents) to increase the absorption and effectiveness of the medication must keep this in mind.^{19,43} The use of stents is contraindicated for up to 6 weeks post-surgery in order to avoid pressure necrosis or dislodgment of the graft.

The success of the mucogingival procedures presented in this report may be due to: 1) timely resolution of the gingival lesions; 2) the relatively short-term use of the topical steroid prior to surgery; 3) limited detrimental effects of the steroid due to physical removal within the oral cavity; and 4) careful manipulation and postoperative management of the tissues.

CONCLUSION

This report demonstrates the successful treatment of multiple recessions in a patient with cicatricial pemphigoid. In patients with suspected mucocutaneous disorders, it is imperative to establish a definitive diagnosis via histopathologic and immunologic findings. The goal of treatment should focus on eradication of the lesions prior to any periodontal surgery or

restorative interventions. Treatment regimens should be conservative, using the minimal doses of topical and systemic steroids necessary to achieve resolution of the lesions. This will then minimize possible adverse effects that may compromise the success of surgical therapy.

ACKNOWLEDGMENTS

The authors would like to thank Dr. E. James Cundiff II (Baylor College of Dentistry-TAMUS Department of Pathology) for the histopathology slides; Dr. Jeff G. Detweiler (ProPath Services, Ft. Worth, TX) for the direct immunofluorescence microscopy slides; and Patty Rowan (Laboratory Medicine/Pathology Department, Harris Hospital Southwest, Ft. Worth, TX) for laboratory technical support.

REFERENCES

1. Nisengard RJ, Rogers RS. The treatment of desquamative gingival lesions. *J Periodontol* 1987;58:167-172.
2. Frith PA, Venning VA, Wojnatowska F, Millard PR, Bron AJ. Conjunctival involvement in cicatricial and bullous pemphigoid: A clinical and immunopathological study. *Br J Ophthalmol* 1989;73:52-56.
3. Tauber J, Melamed S, Foster CS. Glaucoma in patients with ocular cicatricial pemphigoid. *Ophthalmol* 1989;96:33-37.
4. Hanson RD, Olsen KD, Rogers RS. Upper aerodigestive tract manifestations of cicatricial pemphigoid. *Ann Otol Rhinol Laryngol* 1988;97:493-499.
5. Mantou SL, Scully C. Mucous membrane pemphigoid: An elusive diagnosis? *Oral Surg Oral Med Oral Pathol* 1988;66:37-40.
6. Lamey P-J, Rees TD, Binnie WH, Rankin KV. Mucous membrane pemphigoid. Treatment experience at two institutions. *Oral Surg Oral Med Oral Pathol* 1992;74:50-53.
7. Williams DM. Vesiculo-bullous mucocutaneous disease: Benign mucous membrane and bullous pemphigoid. *J Oral Pathol Med* 1990;19:16-23.
8. Fine J-D, Neises GR, Katz SI. Immunofluorescence and immunological microscopic studies in cicatricial pemphigoid. *J Invest Dermatol* 1984;82:39-43.
9. Venning VA, Frith PA, Millard PR, Wojnatowska F. Mucosal involvement in bullous and cicatricial pemphigoid: A clinical and immunopathological study. *Br J Dermatol* 1988;118:7-15.
10. Yih W-Y, Maier T, Kratochvil FJ, Zieper MB. Analysis of desquamative gingivitis using direct immunofluorescence in conjunction with histology. *J Periodontol* 1998;69:678-685.
11. Nisengard RJ. Periodontal implications: Mucocutaneous disorders. *Ann Periodontol* 1996;1:401-438.
12. Lozada-Nur F, Miranda C, Maliksi R. Double-blind clinical trial of 0.05% clobetasol propionate ointment in orabase and 0.05% fluocinonide ointment in orabase in the treatment of patients with oral vesiculoerosive diseases. *Oral Surg Oral Med Oral Pathol* 1994;77:598-604.
13. Rogers RS III, Seehafer JR, Perry HO. Treatment of cicatricial (benign mucous membrane) pemphigoid with dapsone. *J Am Acad Dermatol* 1982;6:215-223.
14. Chaikin BS. A treatment of desquamative gingivitis by the use of free gingival grafts. *Quintessence Int* 1980;9:105-109.
15. Pini Prato GP, de Paoli S, Giannotti B. A case of lichen planus: A clinical and histologic investigation during periodontal surgery. *Int J Periodontics Restorative Dent* 1984;4(5):51-63.
16. Brain JH, Paul BF, Assad DA. Periodontal plastic surgery in a dystrophic epidermolysis bullosa patient: Review and case report. *J Periodontol* 1999;70:1392-1396.
17. Allen EP. Pedicle flaps, gingival grafts, and connective tissue grafts in aesthetic treatment of gingival recession. *Practical Periodontics Aesthetic Dent* 1993;5:29-38.
18. Lorenzana ER, Allen EP. The single incision palatal harvest technique: A strategy for esthetics and patient comfort. *Int J Periodontics Restorative Dent* 2000;20:297-305.
19. Lilly JP, Spivey JD, Fotos PC. Benign mucous membrane pemphigoid with advanced periodontal involvement: Diagnosis and therapy. *J Periodontol* 1995;66:737-741.
20. Meyer JR, Miglioratti CA, Daniels TD, Greenspan JS. Localization of basement membrane components in mucous membrane pemphigoid. *J Invest Dermatol* 1985;84:105-107.
21. Consensus report on mucocutaneous disorders. *Ann Periodontol* 1996;1:439-442.
22. Wennstrom JL. Mucogingival therapy. *Ann Periodontol* 1996;1:671-701.
23. Langer B, Langer L. Subepithelial connective tissue graft technique for root coverage. *J Periodontol* 1985;56:715-720.
24. Harris RJ. The connective tissue with partial thickness double pedicle graft: The results of 100 consecutively treated defects. *J Periodontol* 1994;65:448-461.
25. Champion RH, Burton JL, Ebling FJG, eds. *Textbook of Dermatology*, 5th ed. Boston: Blackwell Scientific Publications; 1992:1767.
26. Devitt H, Clark MA, Marks R, Picton W. A quantitative approach to epidermal wound healing: The effect of dexamethasone on regenerating epithelium. *Br J Dermatol* 1978;98:315-323.
27. Koob TJ, Jeffrey JJ, Eisen AZ. Regulation of human skin collagenase activity by hydrocortisone and dexamethasone in organ culture. *Biochem Biophys Res Commun* 1974;61:1083-1088.
28. Pinnel SR. Regulation of collagen synthesis. *J Invest Dermatol* 1982;69:73-76.
29. Risteli J. Effect of prednisolone on the activities of intracellular enzymes of collagen biosynthesis in rat skin. *Biochem Pharmacol* 1977;26:1295-1298.
30. Marks JG Jr., Cano C, Leitzel K, Lipton A. Inhibition of wound healing by topical steroids. *J Dermatol Surg Oncol* 1983;9:819-821.
31. Winter GD. Epidermal regeneration studies in the

- domestic pig. In: Maibach HI, Rovee CT, eds. *Epidermal Wound Healing*. Chicago: Year Book Medical Publishers;1972:71-112.
32. Berliner DL, Ruhmann AG. Comparison of the growth of fibroblasts under the influence of 11 β -hydroxy and 11-keto corticosteroids. *Endocrinol* 1966;78:373-382.
 33. Du Vivier A, Phillips H, Hehir M. Application of glucocorticosteroids. The effect of twice-daily versus once-every-other-day applications on mouse epidermal cell DNA synthesis. *Arch Dermatol* 1980;163:216-222.
 34. Nguyen H, Lim J, Dresner ML, Nixon B. Effect of local corticosteroids on early inflammatory function in surgical wound of rats. *J Foot Ankle Surg* 1998;37:313-318.
 35. Miller JA, Levene GM. Steroids in dermatology. *Br J Hosp Med* 1982;28:331-338.
 36. Marshall RC, Du Vivier A. The effects of epidermal DNA synthesis of the butyrate esters of clobetasone and clobetasol and the propionate ester of clobetasol. *Br J Dermatol* 1978;98:355-359.
 37. Dykes PJ, Marks R. Measurements of skin thickness: A comparison of 2 in vivo techniques. *J Invest Dermatol* 1977;69:275-278.
 38. Burton JL, Winter GD. Experimentally induced steroid atrophy in the domestic pig and man. *Br J Dermatol* 1976;94(Suppl. 12):107-109.
 39. Marks R, Halprin K, Fukui K, et al. Topically applied triamcinolone and macromolecular synthesis by human epidermis. *J Invest Dermatol* 1971;56:470-473.
 40. Lehman P, Zheng P, Lavker RM. Corticosteroid atrophy in human skin. A study by light, scanning and transmission electron microscopy. *J Invest Dermatol* 1983; 81:169-179.
 41. Tan CY, Marks R, Payne P. Comparison of xeroradiographic and ultrasound detection of corticosteroid induced dermal thinning. *J Invest Dermatol* 1981;76: 126-128.
 42. Delescluse J, van der Endt JD. A comparison of the safety, tolerability, and efficacy of fluticasone propionate ointment, 0.005%, and betamethasone-17,21-dipropionate ointment, 0.05%, in the treatment of eczema. *Cutis* 1996;57(Suppl. 2):32-38.
 43. Lamey P-J, Jones CM. Desquamative gingivitis treated with occlusive steroid therapy: A pilot study. *Gerodontology* 1988;4:188-190.

Send reprint requests to: Dr. Eduardo R. Lorenzana, 4871 Fredericksburg Road, San Antonio, TX 78229. Fax: 210/349-5844; e-mail: doctors@advancedperiodontics.com

Accepted for publication July 7, 2000.